

Fibroblasts in Head and Neck Squamous Cell Carcinoma Associated With Perineural Invasion Have High-Level Nuclear Yes-Associated Protein (YAP) Expression

Yanghua Wang, MD, PhD¹, Adam Gersten, MD¹, Susana Moleirinho, PhD^{2,3}, Frank J. Gunn-Moore, PhD², Paul A. Reynolds, PhD³, and Michael B. Prystowsky, MD, PhD¹

Academic Pathology
October-December 2015: 1-5
© The Author(s) 2015
Reprints and permission:
sagepub.com/journalsPermissions.nav
DOI: 10.1177/2374289515616972
apc.sagepub.com



Abstract

We retrospectively studied the expression of Yes-associated protein (YAP) using immunohistochemical staining in 10 cases of head and neck squamous cell carcinoma with associated perineural invasion. We find that fibroblasts in areas associated with perineural invasion show higher levels of nuclear YAP compared to fibroblasts in the stroma of normal mucosa, with a median cell count of 35.4 per high-power field in the former and 3.9 in the latter. No differences were observed between the expression of YAP phosphorylated at Ser127 in the tumoral stroma compared to that in the normal mucosa, with a median cell count expression of 4.9 in the former versus 5.0 in the latter. Therefore, a strong and increased nuclear YAP expression in fibroblasts associated with perineural invasion in head and neck squamous cell carcinoma suggests that YAP-mediated transcription programs in these fibroblasts may contribute to perineural invasion.

Keywords

fibroblast, perineural invasion, squamous cell carcinoma, YAP expression

Received July 09, 2015. Received revised October 05, 2015. Accepted for publication October 21, 2015.

Introduction

The tumor microenvironment plays an important role in the growth and invasive properties of tumors,¹ recently reviewed factors contributing to squamous cell carcinoma invasion in the head and neck including cancer-associated fibroblasts (CAFs). Fibroblasts within a tumor, CAFs, are an important component of the tumor stroma, contributing to both the extracellular matrix (ECM) and the release of growth factors that promote tumor growth and invasion.²⁻⁶ YAP is a transcriptional coactivator known to partner with Transcriptional enhancer associate domain (TEAD) and other transcription factors to regulate gene expression. In response to Hippo signaling, YAP is phosphorylated at Ser127 (pYAP) and retained in the cytoplasm by 14-3-3-dependent cytoplasmic sequestration, preventing the activation of YAP-mediated transcription programs that regulate cell

proliferation, cell death, and cell fate decisions.^{6,9} Additionally, ECM rigidity, cell tension, and changes in cell geometry activate a YAP-dependent mechanoreponse independent of Hippo signaling.^{7,8}

Previous studies have shown elevated YAP expression in tumor cells, for example, YAP is strongly expressed in tumor

¹ Department of Pathology, Albert Einstein College of Medicine/Montefiore Medical Center, Bronx, NY, USA

² School of Biology, University of St Andrews, Scotland, United Kingdom

³ School of Medicine, University of St Andrews, Scotland, United Kingdom

Corresponding Author:

Michael B. Prystowsky, MD, PhD, Albert Einstein College of Medicine/Montefiore Medical Center, Bronx, NY, USA.

Email: michael.prystowsky@einstein.yu.edu



Creative Commons CC-BY-NC: This article is distributed under the terms of the Creative Commons Attribution-NonCommercial 3.0 License (<http://www.creativecommons.org/licenses/by-nc/3.0/>) which permits non-commercial use, reproduction and distribution of the work without further permission provided the original work is attributed as specified on the SAGE and Open Access page (<https://us.sagepub.com/en-us/nam/open-access-at-sage>).

cell islands in basal cell carcinoma,^{9,10} but YAP is also expressed in fibroblasts, such as peripheral nerve fibroblasts,¹¹ and YAP has been implicated in lung fibroblast activation and fibrosis.¹² Both total and nuclear YAP (nYAP)-increased expression are associated with poor patient survival in numerous cancers, suggesting that YAP expression may have prognostic value.⁸ Recent evidence from fibroblasts within mouse mammary tumors at different stages of progression that show increased nYAP suggests that YAP may have a tumor-promoting role in fibroblasts within a tumor, in addition to its more established role in epithelial cells.¹³

In the present study, we investigated the expression of YAP and pYAP in fibroblasts at the sites of perineural invasion in head and neck squamous cell carcinoma compared to fibroblasts in the stroma of normal mucosa and previous biopsy sites. We find that fibroblasts in areas associated with perineural invasion show higher levels of nYAP compared to fibroblasts in the stroma of normal mucosa, suggesting that YAP-mediated transcription programs in these fibroblasts may contribute to perineural invasion.

Materials and Methods

Tissue Samples

For this initial case series study, we selected 10 cases of head and neck squamous cell carcinoma with perineural invasion from our head and neck cancer database of over 500 cases. The patients were mostly elderly males with a mean age of 71.1 years and a male to female ratio of 9 to 1. Paraffin blocks were retrieved from the files of the Department of Pathology at Montefiore Medical Center, Albert Einstein College of Medicine, Bronx, New York. The Institutional Review Board of Montefiore Medical Center, Bronx, New York, granted us the permission to use clinical information and tissue samples for research purposes.

All tissues were routinely fixed in 10% buffered formalin and embedded in paraffin. The YAP (catalog number 4912) and phospho-YAP (Ser127 catalog number 4911) antibodies are from Cell Signaling, (Danvers, MA), whereas the secondary antibody Dako Envision+ system—horseradish peroxidase-labeled polymer and anti-rabbit and chromogen 3,3'-diaminobenzidine (DAB) substrate kit are from Dako Co. (Carpinteria, CA). The expressions of YAP and pYAP were assessed in stroma from areas of previous biopsy site reaction and tumoral stroma.

Immunohistochemical Stain

The paraffin sections were cut at 5 μ m thickness and were placed on positively charged slides. Slides were placed in a 60°C oven for an hour and then deparaffinized and rehydrated through a series of xylene and graded alcohols. Endogenous peroxidase was quenched in 3% H₂O₂ for 10 minutes. Antigen retrieval was performed by placing the slides in an Oster (Boca Raton, FL) vegetable steamer with Cell Marque (Rockline, CA) Trilogy solution for YAP and Dako Target Retrieval Solution

Table 1. YAP and pYAP-Positive Fibroblasts in Tumoral Stroma Versus Benign Stroma*.

Case	YAP (Positive Cells/HPF)		p-YAP (Positive Cells/HPF)	
	Benign Stroma	Tumoral Stroma	Benign Stroma	Tumoral Stroma
1	6.8	11.2	5.3	17.0
2	8.6	42	4.0	5.0
3	0.6	69.4	9.6	6.0
4	2.8	45.1	5.4	4.6
5	1.2	46.0	4.6	4.8
6	5.5	37.2	2.8	1.1
7	0.4	33.6	2.6	4.4
8	0	8.0	0	2.0
9	5.0	22.6	9.0	10.4
10	6.4	22.0	14.6	6.6
Median	3.9	35.4	5.0	4.9

Abbreviations: HPF, high-power field; pYAP, phosphorylated at Ser127.
*See Methods.

for phospho-YAP (Ser127). The staining procedure was performed in an automatic slide stainer (Dako Autostainer Plus). The primary rabbit polyclonal antibodies, YAP and phospho-YAP (Ser127), were applied in a dilution of 1:50 for 30 minutes at room temperature followed by a secondary antibody for 30 minutes and DAB substrate as chromogen for 10 minutes. Slides were counterstained with Surgipath (Buffalo Grove, IL) hematoxylin, dehydrated through graded alcohols, cleared in xylene, and coverslipped with Cytoseal 60 from Richard-Allan Scientific (Waltham, MA).

The staining patterns were classified as cytoplasmic or nuclear, and the staining intensity was divided into 4 categories—0: no staining, 1+: weakly stained, 2+: moderately stained, and 3+: strongly stained. Only cells staining as 2+ or 3+ were considered positive. The number of positive fibroblasts at each site, normal stroma and tumoral stroma, was determined by counting the total number of positive cells in 5 high-power fields (HPFs) and calculating the average number of cells per HPF. The median for the average counts at each site for YAP and pYAP is presented in Table 1. Two pathologists performed the assessment of YAP and pYAP expression in the benign and tumoral stroma. There was good concordance between the pathologists, and the results from 1 pathologist are reported in Table 1.

Results

Since YAP has been suggested as a prognostic marker in numerous cancers, YAP expression was examined with a particular focus on CAFs in the tumoral stroma and areas associated with perineural invasion using both an antibody that detects total YAP protein as well as an antibody that specifically detects pYAP.

Analysis of the 10 cases demonstrated CAFs at sites of perineural invasion and in cancer stroma had a higher number of fibroblasts displaying strong nYAP expression compared to

fibroblasts in areas of benign mucosa. Overall, the median fibroblast count with nYAP expression was 35.4 cells/HPF in the tumoral stroma, which was nearly 10 times higher than that found in the benign stroma (3.9 cells/HPF; Table 1). Some pYAP staining was also observed in the CAFs at sites of perineural invasion and cancer stroma, but the levels were lower than that of nYAP. In benign squamous stroma associated with previous biopsy site reaction, there were low levels of fibroblasts with YAP and pYAP staining.

Overall, the expression level of YAP was higher in both CAFs and tumor cells, especially the nYAP. The pYAP was also seen in both CAFs and tumor cells, but mainly in the cytoplasmic location. The expression of YAP and pYAP in CAFs at sites of perineural invasion as well as fibroblasts in the tumoral stroma and benign mucosal stroma are shown (Figures 1 and 2).

Discussion

We studied the expression of YAP and pYAP in the tumoral stroma of CAF, CAF associated with perineural invasion, and fibroblasts at normal squamous mucosa and previous biopsy sites. We found that CAF and CAF with perineural invasion had a high YAP expression. It has already been demonstrated that tumors, especially malignant ones that contain a complex ECM due to desmoplastic reactions to the tumor cells, increase stiffness of the ECM, which further enhances tumor invasion and metastasis. The Hippo pathway regulates organ size and tumorigenesis in *Drosophila* and mammals and is altered in a variety of human cancers.^{11,14} In a study of the Hippo pathway in ovarian cancer by Hall and colleagues, the authors found that the effective YAP, specifically high levels of nYAP or low levels of cytoplasmic phosphorylated YAP (cpYAP), was associated with poor survival in patients with ovarian cancer. Consistent with these findings, Steinhardt and colleagues found that nuclear and cytoplasmic YAP protein expression was significantly higher in carcinoma cells of the colon, lungs, and ovaries than in their counterpart benign components, indicating active proliferation.¹⁵ The study by Yeo and colleagues has reported that YAP and pYAP protein expression was increased in breast borderline/malignant phyllodes tumor compared to in benign phyllodes tumor¹⁶ and found that higher nuclear expression of YAP was associated with worse overall and disease-free survival in patients with esophageal squamous cell carcinoma in a Korean population.¹⁶ Most studies investigated YAP protein expression in malignant epithelial or stromal cells. In the study by Calvo et al, the ability of CAFs to promote cancer cell invasion was also significantly dependent on YAP function, whereas Transcriptional co-activator with PDZ-binding motif (TAZ) was not required.¹⁷ The authors also showed that depletion of YAP reduced the ability of CAFs to form fibrous collagen networks and promote angiogenesis in vivo, whereas transforming growth factor β (TGF- β) promoted nuclear accumulation of YAP.¹³

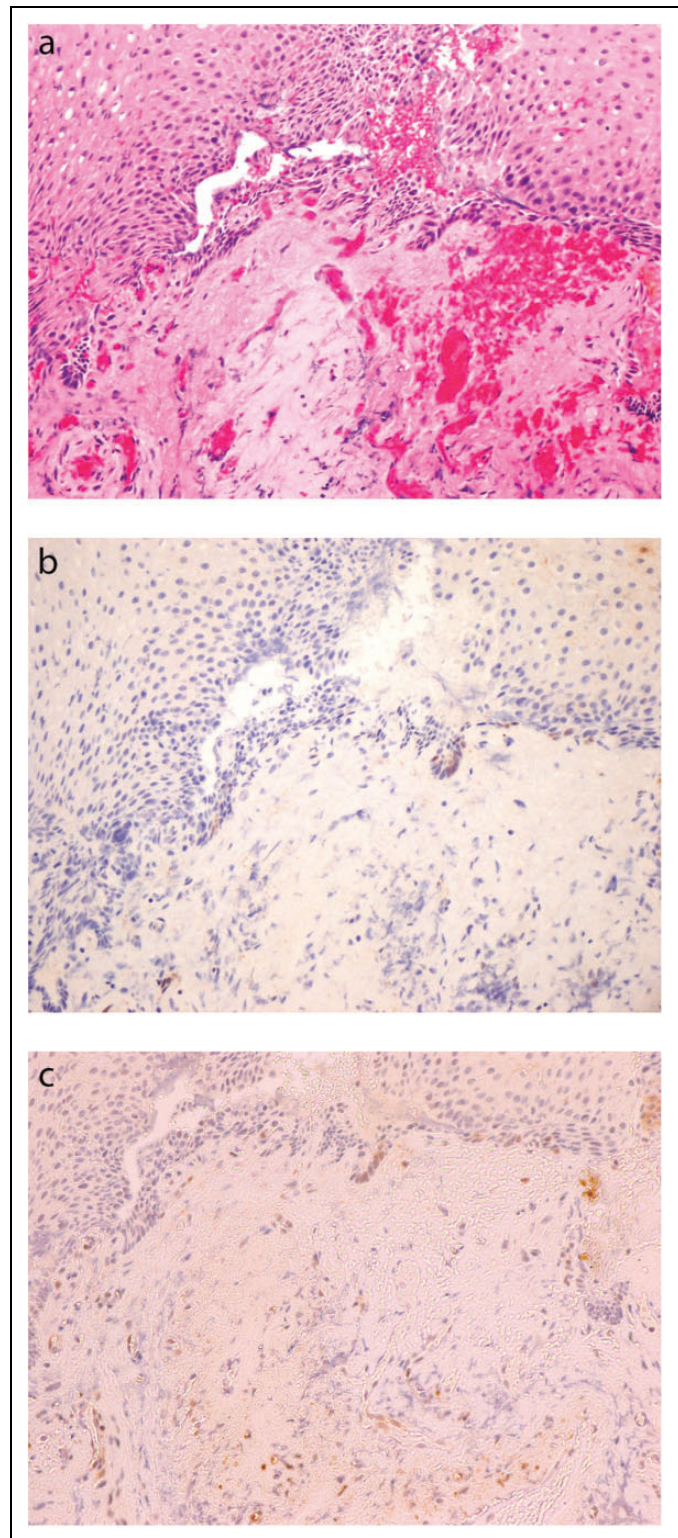


Figure 1. A, Benign squamous cell mucosa, hematoxylin and eosin (H&E) section, $\times 200$. B, Immunostain of YAP, no to rare basal cells and fibroblasts with nuclear and cytoplasmic expression, $\times 200$. C, Immunostain of phosphorylated at Ser127 (pYAP), scattered basal cells and fibroblasts with nuclear and cytoplasmic expression, $\times 200$.

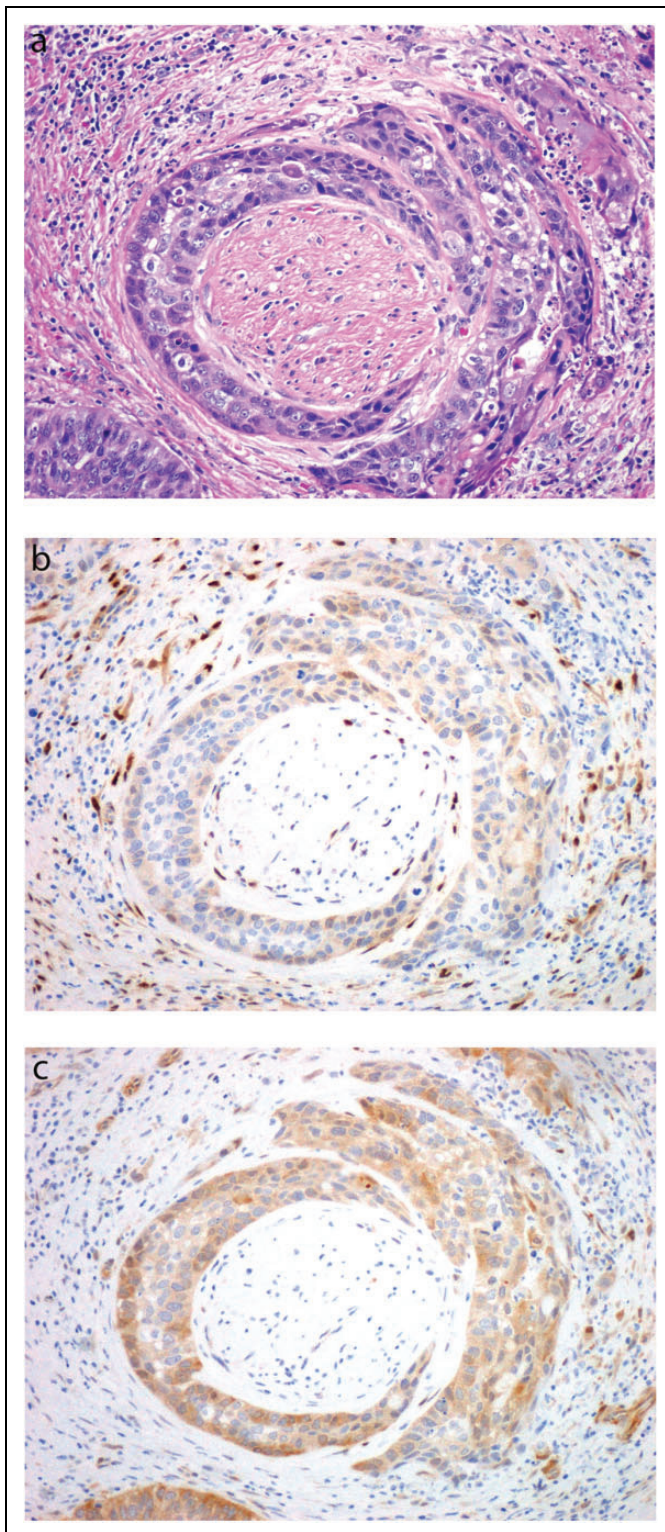


Figure 2. A, Squamous cell carcinoma with perineural invasion, hematoxylin and eosin (H&E) section, $\times 200$. B, Immunostain of YAP, fibroblasts with strong nuclear YAP expression and tumor cells with weak cytoplasmic expression, $\times 200$. C, Immunostain of phosphorylated at Ser127 (pYAP) in the fibroblasts with perineural invasion and fibroblasts and tumor cells with mainly cytoplasmic expression, $\times 200$.

In our study, we found that high level of nYAP in CAFs is associated with perineural invasion, with fibroblasts that have a low level of cpYAP expression indicating a more aggressive pattern of invasion. They also had more extensive desmoplastic stroma composed of inflammatory cells, which might produce some chemokines, cytokines, and TGF- β ,¹⁸ which could be involved in accumulating nYAP in the CAFs. In benign mucosa, no to few fibroblasts are present, and they usually have weak nYAP expression and seem less activated. Our observation was consistent with the finding by others that YAP with a nuclear location was critical for CAFs to produce a rigid collagen network that stimulates and promotes tumor invasion into peripheral nerves.

In conclusion, strong nYAP staining in perineural invasion associated with stromal fibroblasts in head and neck squamous cell carcinoma suggests that YAP-mediated transcription programs may contribute to perineural invasion.

Declaration of Conflicting Interests

The author(s) declared no potential conflicts of interest with respect to the research, authorship, and/or publication of this article.

Funding

The author(s) disclosed receipt of the following financial support for the research, authorship, and/or publication of this article: Paul A. Reynolds, PhD, is supported by the Melville Trust for the Care and cure of Cancer.

References

1. Jimenez L, Jayakar SK, Ow TJ, Segall JE. Mechanisms of invasion in head and neck cancer [published online June 5, 2015]. *Arch Pathol Lab Med.* 2015.
2. Augsten M, Sjoberg E, Frings O, et al. Cancer-associated fibroblasts expressing CXCL14 rely upon NOS1-derived nitric oxide signaling for their tumor-supporting properties. *Cancer Res.* 2014;74:2999-3010.
3. Cheng M, Ho S, Yoo JH, et al. Cathelicidin suppresses colon cancer development by inhibition of cancer associated fibroblasts. *Clin Exp Gastroenterol.* 2015;8:13-29.
4. Comito G, Giannoni E, Segura CP, et al. Cancer-associated fibroblasts and M2-polarized macrophages synergize during prostate carcinoma progression. *Oncogene.* 2014;33:2423-2431.
5. Fukui H, Zhang X, Sun C, et al. IL-22 produced by cancer-associated fibroblasts promotes gastric cancer cell invasion via STAT3 and ERK signaling. *Br J Cancer.* 2014;111:763-771.
6. Shi P, Feng J, Chen C. Hippo pathway in mammary gland development and breast cancer. *Acta Biochim Biophys Sin (Shanghai).* 2015;47:53-59.
7. Piccolo S, Dupont S, Cordenosi M. The biology of YAP/TAZ: hippo signaling and beyond. *Physiol Rev.* 2014;94:1287-1312.
8. Sun Z, Xu R, Li X, et al. Prognostic value of Yes-associated protein 1 (YAP1) in various cancers: a meta-analysis. *PLoS One.* 2015;10:e0135119.
9. Quan T, Xu Y, Qin Z, et al. Elevated YAP and its downstream targets CCN1 and CCN2 in basal cell carcinoma: impact on

- keratinocyte proliferation and stromal cell activation. *Am J Pathol.* 2014;184:937-943.
10. Zeng Z, Hu P, Tang X, et al. Detection and analysis of miRNA expression in breast cancer-associated fibroblasts [in Chinese]. *Xi Bao Yu Fen Zi Mian Yi Xue Za Zhi.* 2014; 30:1071-1075.
 11. Zhao B, Wei X, Li W, et al. Inactivation of YAP oncoprotein by the Hippo pathway is involved in cell contact inhibition and tissue growth control. *Genes Dev.* 2007;21:2747-2761.
 12. Zhu Y, Li D, Wang Y, et al. Brahma regulates the Hippo pathway activity through forming complex with Yki-Sd and regulating the transcription of Crumbs. *Cell Signal.* 2015;27: 606-613.
 13. Yu Y, Xiao CH, Tan LD, Wang QS, Li XQ, Feng YM. Cancer-associated fibroblasts induce epithelial-mesenchymal transition of breast cancer cells through paracrine TGF-beta signalling. *Br J Cancer.* 2014;110:724-732.
 14. Mo JS, Park HW, Guan KL. The Hippo signaling pathway in stem cell biology and cancer. *EMBO Rep.* 2014;15:642-656.
 15. Steinhardt AA, Gayyed MF, Klein AP, et al. Expression of Yes-associated protein in common solid tumors. *Hum Pathol.* 2008; 39:1582-1589.
 16. Yeo MK, Kim SH, Kim JM, et al. Correlation of expression of phosphorylated and non-phosphorylated Yes-associated protein with clinicopathological parameters in esophageal squamous cell carcinoma in a Korean population. *Anticancer Res.* 2012;32: 3835-3840.
 17. Calvo F, Ege N, Grande-Garcia A, et al. Mechanotransduction and YAP-dependent matrix remodelling is required for the generation and maintenance of cancer-associated fibroblasts. *Nat Cell Biol.* 2013;15:637-646.
 18. Liebig C, Ayala G, Wilks JA, Berger DH, Albo D. Perineural invasion in cancer: a review of the literature. *Cancer.* 2009;115: 3379-3391.