



Anatomical and functional study of the *musculus psoas major* and *nervus femoralis* in correlation with pelvic diameters

Anatomska i funkcionalna studija slabinskog mišića i butnog živca u korelaciji sa dijametrima karlice

Aleksandar Vojvodić*, Aleksandar Matić†, Jelena Mihailović‡,
Predrag Bjelogrić§, Laslo Puškaš[¶], Lazar Stijak[¶], Dubravka Aleksić[¶],
Branka Filipović^{¶¶}, Biserka Vukomanović-Djurdjević^{¶††}, Slobodan Kapor[¶]

*Clinical Center of Zemun, Department of Orthopedic Surgery, Belgrade, Serbia;
†University of Kragujevac, Faculty of Medical Sciences, Department of Orthopedic Surgery, Kragujevac, Serbia; ‡Mayo Clinic, Department of Radiology, Rochester, MN, USA; §University of St Andrews, Faculty of Medicine, Department of Anatomy and Clinical Skills, Scotland, UK; ¶University of Belgrade, Faculty of Medicine, Institute of Anatomy “Niko Miljanić”, Belgrade, Serbia; ¶University of Belgrade, Faculty of Medicine, Belgrade, Serbia; ¶¶ University Clinical Hospital Center “Dr Dragiša Mišović – Dedinje“, Department of Gastroenterology, Belgrade, Serbia; ††University of Defence, Faculty of Medicine of the Military Medical Academy, Belgrade, Serbia

Abstract

Background/Aim. The iliopsoas muscle [*musculus (m.) iliopsoas*] originates from the Greek word *psóa*, which means loin and represents the only muscle in the body with anatomical preconditions to simultaneously and directly contribute to the stability and movement of the trunk, pelvis, and legs. *M. iliopsoas* belongs to the inner thigh muscle group and forms part of the posterior abdominal wall. This muscle is the major flexor of the hip joint, and it is functionally essential for proper posture, walking, running, and other physical activities. The aim of this study was to determine the relationship between the anatomical parameters of the pelvis and *nervus (n.) femoralis*, as well as the relationship between the same pelvic parameters and *m. psoas major*. **Methods.** The study was conducted at the Faculty of Medicine, University of Belgrade, on cadaveric material of the Institute of Anatomy “Niko Miljanić”. For measurement purposes, 14 cadavers were used, seven of which were male and seven female, aged 67–79 years. The measuring instruments used in this study were a ruler and an electronic digital caliper (measuring range 0–500 mm, resolution 0.01 mm). Statistical data processing was performed in the SPSS 11.0 program using the Mann-Whitney *U* test.

Apstrakt

Uvod/Cilj. Slabinsko-bedreni mišić [*musculus (m.) iliopsoas*] vodi poreklo od grčke reči *psóa* što znači slabina i predstavlja jedini mišić u telu koji ima anatomske preduslove da

Results. The results of this study indicate a significant statistical difference in pelvic width between male and female cadavers, which was observed in the reduction of the bituberal line in females, while the parameters of the bispinal line showed no significant difference between the two genders. The decrease of the bituberal line in females was followed by an increase in the width of the proximal origin with a statistically significant decrease in the length of the proximal origin of the *m. psoas major*. Furthermore, the vertical distance of *n. femoralis* from the exit point of the muscle to the bispinal line was significantly reduced in the male cadavers. **Conclusion.** Based on our results, we can assume that, in most cases, due to the smaller bituberal and bispinal line or narrower pelvis, a shorter proximal attachment of the *m. psoas major* will occur with greater width (L2–L5 level) in the female than in the male gender, resulting in a longer vertical distance of *n. femoralis*. Such results indicate a close correlation between the anatomical parameters of the *m. psoas major*, which may affect the distance of *n. femoralis* exit from the muscle.

Key words:
anatomy; femoral nerve; pelvis; psoas muscles; sex factors.

istovremeno i direktno doprinosi stabilnosti i pokretu trupa, karlice i nogu. *M. iliopsoas* pripada unutrašnjoj grupi mišića bedra i čini deo zadnjeg trbušnog zida. Ovaj mišić je glavni pregibač (fleksor) u zglobu kuka i funkcionalno je bitan za pravilno držanje tela, hodanje, trčanje i ostale fizičke

aktivnosti. Cilj rada bio je da se ispita povezanost anatomskih dimenzija karlice i butnog živca [*nervus (n.) femoralis*], kao i odnos tih parametara sa proksimalnim pripojem *m. psoas major*-a. **Metode.** Istraživanje je sprovedeno na Medicinskom fakultetu Univerziteta u Beogradu, na kadaverskom materijalu Instituta za Anatomiju „Niko Miljanić“. Za potrebe merenja iskorišćeno je 14 kadavera, sedam kadavera muškog i sedam ženskog pola, starosne dobi od 67–79 godina. Merni instrumenti korišćeni u istraživanju bili su lenjir i elektronski digitalni kaliper (merni opseg 0–500 mm, rezolucija 0,01 mm). Statistička obrada podataka izvršena je u programu SPSS 11.0, primenom Mann-Whitney *U* testa. **Rezultati.** Utvrđena je značajna statistička razlika u širini karlice između kadavera muškog i ženskog pola, koja se manifestovala smanjenjem bituberalne linije kod osoba ženskog pola, dok za dijametar bispinalne linije nije utvrđena značajna razlika između polova. Smanjenje bituberalne linije kod osoba ženskog pola bilo je praćeno

povećanjem širine proksimalnog pripoja *m. psoas major*-a, uz statistički značajno smanjenje dužine proksimalnog pripoja. Takođe, vertikalno rastojanje od mesta izlaska *n. femoralis*-a iz samog mišića do bispinalne linije, bilo je značajno smanjeno u ispitivanom uzorku osoba muškog pola. **Zaključak.** Na osnovu prikazanih rezultata, možemo pretpostaviti da će se kod žena češće, u odnosu na osobe muškog pola, zbog manje bituberalne i bispinalne linije, odnosno uže karlice, javljati kraći proksimalni pripoj *m. psoas major*-a, sa većom širinom (nivo L2–L5), a samim tim i dužim vertikalnim rastojanjem izlaska *n. femoralis*-a u odnosu na bispinalnu liniju. Takvi rezultati ukazuju na to da postoji uska povezanost između anatomskih parametara karlice i varijacija proksimalnog pripoja *m. iliopsoas*-a, što može uticati na rastojanje izlaska *n. femoralis*-a iz mišića.

Ključne reči:
anatomija; *n.femoralis*; karlica; mišići, slabinski; pol, faktor.

Introduction

The iliopsoas muscle [*musculus (m.) iliopsoas*] originates from the Greek word *psóa*, meaning loin, and is the only muscle in the body that has the anatomical prerequisites to simultaneously and directly contribute to the stability and movement of the trunk, pelvis, and legs. It is composed of the large, long muscle (*m. psoas major*) and the thigh muscle (*m. iliacus*), whose muscular fibers converge to form *m. iliopsoas* at the level between L5 and S2 and insert on the lesser trochanter of the femur as the iliopsoas tendon. The other part of *m. iliopsoas* is *m. psoas minor*, which is missing in 40% of cases^{1, 2}. It belongs to the inner group of thigh muscles and forms part of the posterior abdominal wall³. This muscle is the main flexor in the hip joint and is functionally important for proper posture, walking, running, and other physical activities². The muscular fascia that covers *m. iliopsoas* creates fascial connections that anatomically connect the muscle to the various organs of the abdominal cavity as well as the surrounding structures. In the upper part of the trunk, the muscular fascia merges with the fascia of the chest (*fascia endothoracica*), while the posterior attaches to the arched ligament of the diaphragm (*ligament arcuatum mediale*) and the fascia of the quadratus lumborum muscle (*m. quadratus lumborum*)³. Forward and outward, the fascia of *m. iliopsoas* merges with the fascia of the kidneys, pancreas, ascending and descending colon, duodenum, as well as descending aorta and inferior vena cava⁴. According to the previous studies, *m. iliopsoas* was formed from the mesoderm after the eighth week of intrauterine development⁴. The arterial supply of the muscle originates from the common iliac artery as well as its lateral branch, the external iliac artery. *M. psoas major* is supplied by a rich network of arteries derived from the lumbar, iliolumbar, obturator, and femoral artery. The external iliac vein is responsible for venous drainage of blood from *m. iliopsoas*. Nerves for innervation of muscles originate from the lumbar nerve plexus (*plexus lumbalis*), whereby the anterior branches of the lumbar nerves (L1–L3) innervate the *m. psoas major*

and *m. psoas minor*, while the femoral nerve [*nervus (n.) femoralis*] or anterior branches of the lumbar nerve (L1–L4) innervate *m. iliacus*⁴.

M. psoas major is fusiform in shape, descends from the spinal column to the inguinal ligament (*ligamentum inguinale – Pouparti*), and extends to the lesser trochanter, proximal to the femur². In its central part, *m. psoas major* is round and wide in diameter, while towards the distal attachment, the muscle thins. We can distinguish the superficial and the deep parts of the muscle³. The origin of the superficial part is located on the lateral side of the vertebral bodies T12–L5, as well as on the corresponding intervertebral discs. The deep part of the muscle originates from the transverse process of all the lumbar vertebrae². Jeleu et al.⁵ showed that both lumbar muscles depart from the sacrum. *M. psoas major* is in contact with the organs of the abdominal cavity [kidneys, ureters, lymph nodes, the nerves of the lumbar plexus, sympathetic trunk (*truncus sympathicus*), blood vessels of the kidneys, testicles/ovaries, etc.] as well as with the spinal column and the *quadratus lumborum* muscle².

M. iliacus is triangle-shaped and originates in the superior 2/3 of the iliac fossa, posteriorly to the iliac crest, as well as at the iliolumbar ligament (*ligamentum iliolumbale*), where the bundles of *m. iliacus* merge with the bundles of *quadratus lumborum* muscle, and then over the base of the sacrum bone, anterior superior iliac spine, and anterior inferior iliac spine reach the capsule of the hip joint⁶. The bundles of *m. iliacus* are directed towards the tendon of *m. psoas major*, which they join and attach directly at the lesser trochanter⁶.

The *n. femoralis* is the largest and most important branch of the lumbar plexus. *N. femoralis* is formed from the anterior branches of the second, third, and fourth lumbar nerve, which then passes between the *m. psoas major* and *m. iliacus*. Upon entering the thigh, it goes beneath the inguinal ligament, after which it passes through the *lacuna musculorum* along with the lateral cutaneous *n. femoralis* and with *m. iliopsoas*³. It travels alongside the femoral artery. Beneath the inguinal ligament, it splits into anterior and posterior di-

visions. The anterior branches are responsible for the innervation of the skin of the anteromedial thigh as well as for the innervation of the sartorius muscle. The posterior branches are responsible for innervation of the quadriceps femoris muscle, as well as the knee joint muscle (*m. articularis genuus*). The terminal branch of *n. femoralis* is the saphenous nerve. That is the strongest and longest branch responsible for innervation of the skin of the inner part of the lower legs and inner edges of the arch of the feet⁷.

Even though numerous studies deal with the variations of the attachment of *m. iliopsoas* and its relationship with the surrounding structures, no research has been done on the relationship between the dimensions of the proximal attachment of *m. psoas major* and the size of the pelvic bones so far. Furthermore, the relationship of *n. femoralis* with the anatomical parameters of the pelvic bones, which is an important factor in the division of the sciatic nerve, has not been examined in detail. Given that the association of the anatomical parameters of the pelvic bones with the division of the sciatic nerve has already been established, the aim of this study was to investigate the relationship between the anatomical dimensions of the pelvis and *n. femoralis* and establish a relationship of these parameters with the proximal attachment of *m. psoas major*.

Methods

Our study was conducted at the Faculty of Medicine, University of Belgrade, Serbia. It was performed on cadaver material of the Institute of Anatomy "Niko Miljanić". Fourteen cadavers, seven of which were male and seven female, aged 67–79 years, were used for measurement purposes. All cadavers used in this study were taken from regular lab dissections during the student lectures, which were held at the

Institute of Anatomy. First of all, a visual inspection of each cadaver was carried out to exclude samples with deformities or traces of surgery. After fixing in formalin, the cadavers were subjected to careful dissection, following the standard procedure from the dissection manuals. Afterward, two groups were formed, both of which included the 14 lower extremities. The aim was to define the width and length of the proximal attachment of *m. psoas major*, as well as the vertical distance of the exit of *n. femoralis* from the muscle in relation to the parameters of the width of the pelvis. The width of *m. psoas major* was measured at the proximal attachment of the muscle at the level of the intervertebral discs, between the second and third, third and fourth, and fourth and fifth lumbar vertebrae (L2–L3, L3–L4, L4–L5). The average value at the level of all three intervertebral discs was taken as the final result. As the value of the length of the proximal attachment of the muscle, a vertical distance was taken between the lower edge of the vertebral body, to which the first muscle bundle is attached, and the upper edge of the vertebral body, to where the last muscle bundle attaches. The distance between the right and left anterior superior iliac spine, which we defined as the bispinal line, as well as the distance between the two ischial tuberosity (*tuber ischiadicum*), defined as the bituberal line, were used as parameters of the pelvic width. The vertical distance of *n. femoralis* was measured from the exit point of the nerve from the muscle relative to the bispinal line. All parameters were measured on both sides of the cadaver, especially on the side which was better dissected. The measuring instruments used in the study were a ruler and an electronic digital caliper (measuring range 0–500 mm, resolution 0.01 mm)⁸.

The methodology of measurement the tested parameters is presented schematically (Figure 1). All other parameters are shown in Figures 2 and 3. All the data collected is presented in a tabu-

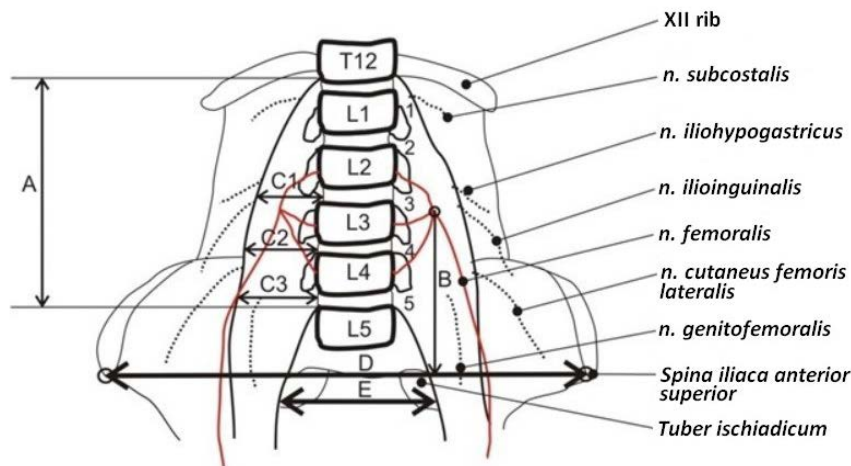


Fig. 1 – An overview of the method of measuring the parameters that were examined in the study. A – distance of the proximal attachment of *musculus (m.) psoas major*; B – vertical distance of the exit of *nervus (n.) femoralis* from the muscle in relation to the bispinal line; C1 – width of the *m. psoas major* at the L2–L3 level of the intervertebral disc; C2 – the width of the *m. psoas major* at the L3–L4 level of the intervertebral disc; C3 – the width of the *m. psoas major* at the L4–L5 level of the intervertebral disc; D – the distance between the two *spinae iliacae anterior superior* (bispinal line); E – the distance between the two ischial tuberosity (bituberal line). The numbers 1–5 show the proximal attachments of *m. psoas major* on the bodies and intervertebral discs of T12–L5.

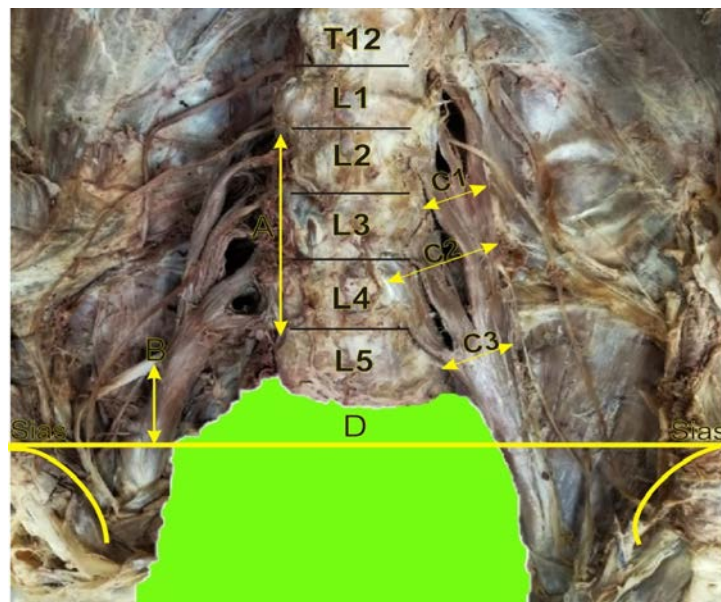


Fig. 2 – An overview of the method of measuring the parameters that were examined in the study. **A** – distance of the proximal attachment of the *musculus (m.) psoas major*; **B** – the vertical distance of the exit of *nervus (n.) femoralis* from the muscles relative to the bispinal line; **C1** – width of *m. psoas major* at the L2–L3 level of the intervertebral disc; **C2** – width of *m. psoas major* at the L3–L4 level of the intervertebral disc; **C3** – width of *m. psoas major* at the L4–L5 level of the intervertebral disc; **D** – the distance between the two *spinae iliaceae anterior superior* (bispinal line); **Sias** – *spina iliaca anterior superior*.

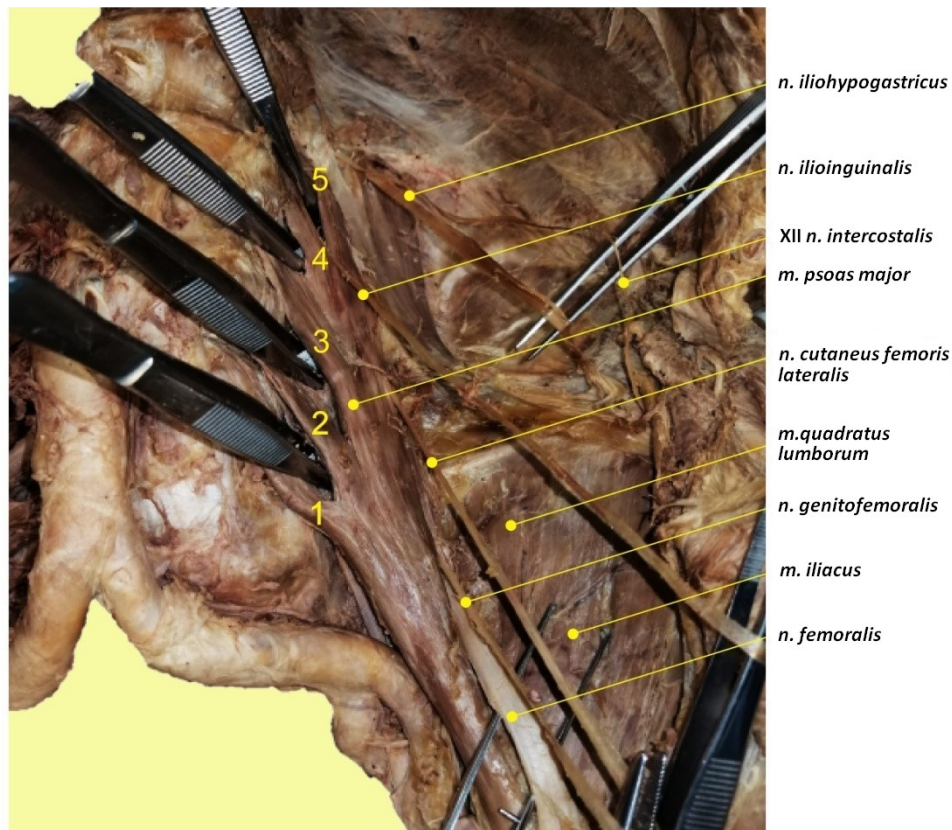


Fig. 3 – Dissection of *musculus (m.) iliopsoas* and nerves (n.) of the lumbar plexus. The numbers 1–5 show the proximal attachment of the bundle of *m. psoas major* on the bodies and intervertebral discs of T12–L5.

Table 1

Mean values of the examined parameters in the male and female group

Parameters	Male	Female
Bispinal line	27.21 ± 3.81	24.50 ± 1.55
Bituberal line	15.79 ± 0.70	14.14 ± 0.80*
Width of the proximal attachment of the <i>musculus psoas major</i>	3.69 ± 0.49	4.64 ± 0.81*
Length of the proximal attachment of the <i>musculus psoas major</i>	15.36 ± 1.41	13.29 ± 1.32*
Vertical distance of <i>nervus femoralis</i> relative to the bispinal line	6.50 ± 0.58	7.86 ± 0.75*

All values (in cm) are expressed as mean ± standard deviation.

* marked statistically significant differences in female cadavers, $p < 0.05$.

lar manner (Table 1). All statistical analysis was carried out in the SPSS 11.0 using the Mann-Whitney U test, where the accepted level of statistical significance was $p < 0.05$, and $p < 0.001$ was accepted for a highly statistically significant result⁸.

Results

The measured parameters are presented in Table 1. The study examined the 14 lower extremities on the right side of the cadaver, with the sample being the seventh male cadaver and the seventh female cadaver. The mean value of the bispinal line in the male group was 27.21 ± 3.81 cm, while in the female group, it measured 24.50 ± 1.55 cm without a statistically significant difference between the groups ($p = 0.259$). The mean value of the bituberal line in the male group was 15.79 ± 0.70 cm, and in the female group, it was 14.14 ± 0.80 cm. Comparing this parameter in the two test groups, we obtained a statistically significant difference ($p = 0.004$). The mean value of the width of the proximal attachment at the levels of L2–L3, L3–L4, and L4–L5 (see the Methods section for more details) in the male group was 3.69 ± 0.49 cm, while the same parameter in the female group was 4.64 ± 0.81 cm. There was an increase in the width of the proximal attachment of *m. psoas major* in the female group with a statistically significant difference ($p = 0.038$) (Table 1). The mean value of the length of the proximal attachment (see the Method section for more details) was 15.36 ± 1.41 cm in the male and 13.29 ± 1.32 cm in the female group. The length of the proximal attachment was lesser in the female group with statistical significance ($p = 0.017$). The vertical distance from the exit point of *n. femoralis*, from *m. psoas major* to the bispinal line, was higher in the female group compared to the male group, with a statistically significant difference ($p = 0.007$) (Table 1). There is a significant statistical difference in pelvic width between male and female cadavers, which is observed in the shorter bituberal line in the female gender, while the diameter of the bispinal line does not make significant differences between the two genders. The shorter bituberal line in the female gender is accompanied by a greater width of the proximal attachment of *m. psoas major* with a statistically significant shorter length of the proximal attachment. Moreover, the distance from the exit point of *n. femoralis* from the muscle itself to the bispinal line was significantly reduced in the male group of the examined sample.

Discussion

Due to its anatomical characteristics, *m. iliopsoas* is described as an axioappendicular muscle that connects the axial and the appendicular skeleton. It is functionally involved in the movements of the trunk, pelvis, and lower extremities and is considered the main flexor in the hip joint⁴. Coactivation of the muscle significantly contributes to the stabilization of the hip joint by pressing the head of the femur into the acetabulum⁹. Neuromuscular diseases of this muscle can lead to dysfunction of the colon, which causes compression of *n. femoralis* and lateral cutaneous *n. femoralis*¹⁰.

M. psoas major contains all three types of muscle fibers that are managed in different directions. The previous study by Johnson et al.¹¹ found an equal ratio of muscle fibers Type I and Type II (49.2% and 50.08%, respectively). Kimura¹² showed the highest prevalence of Type I fibers (42%) compared to Type II (33%) and Type III (25%). Furthermore, they found that Type I fibers are significantly wider in diameter than Type II fibers. Zheng et al.¹³ used histochemical staining of myosin adenosine triphosphate for the fiber typing and described 58% of Type I, 32% of Type II A, and 10% of Type II B fiber. It is believed that there is a difference in muscle fibers in relation to the height of the attachment, whereby in the proximal to the distal attachment, the number of slow muscle fibers decreases (Type II), while the number of fast fibers (Type II and III) increases¹³. This structure can indicate differences in the length of the proximal attachment of the muscle itself as well as the width at the level of L2–L5, which was shown in our study. These results could explain impairment in the dual function of the muscle in males and females due to the different dimensions of the pelvis. The postural function, represented by the proximal part of the muscle, is responsible for stabilizing the lumbar spine and pelvis, while the dynamic function in the distal attachment of the muscle is responsible for movement¹⁴.

Measured bone parameters of the pelvis showed a mean value of the bispinal line (27.21 ± 3.81 cm) and the bituberal line (15.79 ± 0.70 cm), which was higher in the male, compared with the bispinal line (24.50 ± 1.55 cm) and the bituberal line (14.14 ± 0.80 cm) of the female group. We found statistically significant differences in bituberal line values between the male and female groups. The mean width of the proximal attachment of the iliopsoas was lower in the male compared to the female group (3.69 ± 0.49 and 4.64 ± 0.81 cm, respectively). There is also a significant difference ($p = 0.017$) in the length of the proximal muscle attachment,

which was greater in the male group, 15.36 ± 1.41 cm, while in the female group, it was 13.29 ± 1.32 cm. Analyzing the vertical distance of the point where *n. femoralis* exits the muscle to the bispinal line, we found a longer distance in females with $p < 0.007$.

Kepler et al.¹⁵ analyzed the distance between *n. femoralis* and *m. psoas major* from the front of the spinal column. Their results showed that the distance between *n. femoralis* and the front of the spinal column was 3.35 cm at the L3–L4 level, 2.68 cm at the L4–L5 level, and 0.62 cm at the L5–S1 level. The distance of the *m. psoas major* is 0.81 cm at the L1–L2 level, 0.38 cm at the L3–L4 level, 1.16 cm at the L4–L5 level, and 3.15 cm at the L5–S1 level. Another study showed that *n. femoralis* goes lateral to the *m. psoas major*, just below the bifurcation of the common iliac artery, whereby the examined distance between *n. femoralis* and genitofemoral in relation to the common iliac artery showed no statistically significant difference¹⁶. Regev et al.¹⁷ found safe anatomical zones of the weak lumbar nerves on *m. psoas major*, located at the level of L2–L3. These findings are similar to our results, which show the significant difference in the width of the muscle and, at the same time, the distance of the exit point of *n. femoralis* from the muscle in the two tested groups of cadavers. This safe anatomical zone is of great importance during retroperitoneal surgical procedures, where no damage should be made to the lumbar nerves, especially to *n. femoralis*¹⁷. Kirchmair et al.¹⁸ showed that in 47 out of 63 cases, *n. femoralis* could be found as a separate nerve, with no lateral branches larger than 0.2 cm in diameter. In all 47 cases, *n. femoralis* was found at the exit point from *m. psoas major*. In 13 out of 63 cases, the division of *n. femoralis* into two or three branches directly emerging from *m. psoas major* was found¹⁸. The close relationship of *m. iliopsoas* with the largest branch of the lumbar plexus, *n.*

femoralis, is of exceptional clinical importance. A detailed study on variations of *m. iliopsoas* and *n. femoralis* itself might be helpful in fasciotomy or the treatment of hematomas and abscesses in the lumbar region¹². Contractions, tension, and shortening of muscles are also clinically significant as they can lead to a series of disruptions and compression of surrounding structures¹⁰. A study led by Güvencer et al.¹⁹ on the relationship between the anatomical structures of the pelvic bone and the sciatic nerve was conducted first in the anatomical position and then in the positions that simulate the stretching test in the hip joint, such as 60° flexion, 30° adduction, and 10° internal rotation of the hip joint. It has been shown that the biomechanics of the stretching test lead to the infrapiriform foramen narrowing, the sciatic nerve becoming closer to the ischial spine, and the angle between the sciatic nerve and the transversal plane becoming larger, thus creating conditions in which the nerve is more susceptible to being “stuck”. Consequently, in the interpretation and analysis of the results, biomechanics should be considered, which could be the reason for the observed differences in the examined parameters in our study.

Conclusion

Based on our results, we can conclude that females, in most cases, due to a smaller bituberal and bispinal line, i.e., narrower pelvis, will experience a shorter proximal attachment of the *m. psoas major*, with a greater width at the L2–L5 level relative to the males and, therefore, a longer vertical exit distance of *n. femoralis* relative to the bispinal line. Such results indicate a close correlation between the anatomical parameters of the pelvis and variations of the proximal attachment of *m. psoas major*, which may affect the distance of the exit of *n. femoralis* from the muscle.

REFERENCES

1. Andersson E, Oddsson L, Grundström H, Thorstensson A. The role of the psoas and iliacus muscles for stability and movement of the lumbar spine, pelvis and hip. *Scand J Med Sci Sports* 1995; 5(1): 10–6.
2. Arbanas J, Starčević-Klasan G, Malnar D. Composition of the psoas major muscle regarding its complex function. *Med Flum* [Internet] 2012 [accessed on: 2023 June 29]; 48(2): 123–30. Available from: <https://hrcak.srce.hr/84186> (Croatian)
3. Bordoni B, Varacallo M. Anatomy, Bony Pelvis and Lower Limb, Iliopsoas Muscle. [updated 2023 Apr 24]. In: StatPearls [Internet]. Treasure Island (FL): StatPearls Publishing; 2023. [cited 2023 May]. Available from: <https://www.ncbi.nlm.nih.gov/books/NBK531508/>
4. Mrvaljević D. Anatomy of the lower limb. 2nd edition. Belgrade: Faculty of Medicine, University of Belgrade; 2018. p.31–4.
5. Jeleč L, Shinarov V, Surchev L. Bilateral variations of the psoas major and the iliacus muscles and presence of an undescribed variant muscle—accessory iliopsoas muscle. *Ann Anat* 2005; 187(3): 281–6.
6. Siccardi MA, Tariq MA, Valle C. Anatomy, Bony Pelvis and Lower Limb: Psoas Major. [updated 2022 Aug 8]. In: StatPearls [Internet]. Treasure Island (FL): StatPearls Publishing; 2018 [cited 2018 Dec 13]. Available from: <https://www.ncbi.nlm.nih.gov/books/NBK535418/>
7. Basinger H, Hogg JP. Anatomy, Abdomen and Pelvis: Femoral Triangle. [updated 2023 Mar 11]. In StatPearls [Internet]. Treasure Island (FL): StatPearls Publishing; 2019 [cited 2019 Apr 29]. Available from: <https://www.ncbi.nlm.nih.gov/books/NBK541140/>
8. Kapor S, Pnuškaš L, Vojvodić A, Mališ M, Bjelogrić P, Čezayirli E, et al. Anatomically high division of sciatic nerve and its clinical significance. *Vojnosanit Pregl* 2021; 78(10): 1060–4.
9. Yoshio M, Murakami G, Sato T, Sato S, Noriyasu S. The function of the psoas major muscle: passive kinetics and morphological studies using donated cadavers. *J Orthop Sci* 2002; 7(2): 199–207.
10. Laible C, Swanson D, Garofolo G, Rose DJ. Iliosposas Syndrome in Dancers. *Orthop J Sports Med* 2013; 1(3): 2325967113500638.
11. Johnson MA, Polgar J, Weightman D, Appleton D. Data on the distribution of fibre types in thirty-six human muscles: An autopsy study. *J Neurol Sci* 1973; 18(1): 111–29.
12. Kimura T. Composition of psoas major muscle fibers compared among humans, orangutans and monkeys. *Z Morphol Anthropol* 2002; 83(2–3): 305–14.
13. Zheng A, Rabkila P, Vuori J, Rasi S, Takala T, Väinänen HK. Quantification of carbonic anhydrase III and myoglobin in different fiber types of human psoas muscle. *Histochemistry* 1992; 97(1): 77–81.

14. *Arbanas J, Klasan GS, Nikolić M, Jerković R, Mićanović I, Malnar D.* Fibre type composition of the human psoas major muscle with regard to the level of its origin. *J Anat* 2009; 215(6): 636–41.
15. *Kepler CK, Bogner EA, Herzog RJ, Huand RC.* Anatomy of the psoas muscle and lumbar plexus with respect to the surgical approach for lateral transpsoas interbody fusion. *Eur Spine J* 2011; 20(4): 550–6.
16. *Mladonado P, Slocum PD, Chin K, Corton M.* Anatomic relationships of psoas muscle: clinical applications to psoas hitch ureteral reimplantation. *Am J Obstet Gynecol* 2014; 211(5): 563. e1–6.
17. *Regev GJ, Chen L, Dhawan M, Lee YP, Garfin SR, Kim CW.* Morphometric Analysis of the ventral nerve roots and retroperitoneal vessels with respect to the minimally invasive lateral approach in normal and deformed spines. *Spine (Phila Pa 1976)* 2009; 34(12): 1330–5.
18. *Kirchmair L, Lirk P, Colvin J, Mitterschiffthaler G, Moriggl B.* Lumbar plexus and psoas major muscle: not always as expected. *Reg Anesth Pain Med* 2008; 33(2): 109–14.
19. *Güvençer M, Akyer P, Iyem C, Tetik S, Naderi S.* Anatomic considerations and the relationship between the piriformis muscle and the sciatic nerve. *Surg Radiol Anat* 2008; 30(6): 467–74.

Received on November 29, 2022

Revised on April 20, 2023

Accepted on April 25, 2023

Online First April 2023